

BROOKE K. COOMBES, PhD^{1,2} • LEANNE BISSET, PhD³ • BILL VICENZINO, PhD²

Management of Lateral Elbow Tendinopathy: One Size Does Not Fit All

Pain over the lateral epicondyle of the humerus during loading of the wrist extensor muscles is a common musculoskeletal presentation in men and women between 35 and 54 years of age.⁴³ The above symptom is associated with a clinical diagnosis of lateral elbow tendinopathy (LET), also known as tennis elbow or lateral epicondylalgia. Lateral elbow tendinopathy affects approximately 1% to 3% of the general



population,^{43,99,116} with individuals who smoke,⁹⁹ manual workers,⁶³ and tennis players⁴¹ being at increased risk. Lateral elbow tendinopathy results in significant functional disability from work, sports, and leisure activities, and high costs due to productivity loss and health care use.⁹⁹ to 90% of patients assigned to a wait-and-see approach reported significant improvement, although not always complete resolution, in the condition within a year.^{11,102} However, up to a third of patients have prolonged discomfort lasting in excess of 1 year despite interventions, and a considerable proportion of patients experience recurrence of their symptoms following the initial episode.^{9,14,50} Estimates suggest that up to 5% of patients do not respond to conservative physical interventions and undergo surgery, with variable outcomes reported in the literature.^{55,61}

There is a lack of consensus on the best treatment approach for LET, resulting in frustration for patients and practi-

tioners alike.^{64,101} Complexities associated with the anatomy, biomechanics, and pathophysiology of LET have resulted in numerous treatment options described in the literature. One of the challenges in managing LET is the wide range of prognoses among individuals with the condition. For many patients, symptoms of LET are self-limiting, with randomized controlled trials indicating that 83%

In this clinical commentary, we collate existing knowledge of the pathophysiology, clinical presentation, and differential diagnosis of LET. We propose that applying a single intervention, or a one-size-fits-all approach, to all presentations of LET is unlikely to be effective in every case. Instead, interventions should be tailored to the pathology and clinical presentation of the condition. To this end, we highlight 6 factors that may provide direction for physical rehabilitation. Finally, a preliminary algorithm for management of subgroups of patients with LET is proposed as a clinical decision-making guide, though it will require further refinement and validation.

● **SYNOPSIS:** Clear guidelines for the clinical management of individuals with lateral elbow tendinopathy (LET) are hampered by many proposed interventions and the condition's prognosis, ranging from immediate resolution of symptoms following simple advice in some patients to long-lasting problems, regardless of treatment, in others. This is compounded by our lack of understanding of the complexity of the underlying pathophysiology of LET. In this article, we collate evidence and expert opinion on the pathophysiology, clinical presentation, and differential diagnosis of LET. Factors that might provide prognostic value or direction for physical rehabilitation, such as the presence of neck pain, tendon tears, or central sensitization,

are canvassed. Clinical recommendations for physical rehabilitation are provided, including the prescription of exercise and adjunctive physical therapy and pharmacotherapy. A preliminary algorithm, including targeted interventions, for the management of subgroups of patients with LET based on identified prognostic factors is proposed. Further research is needed to evaluate whether such an approach may lead to improved outcomes and more efficient resource allocation. *J Orthop Sports Phys Ther* 2015;45(11):938-949. Epub 17 Sep 2015. doi:10.2519/jospt.2015.5841

● **KEY WORDS:** epicondylalgia, prognosis, tennis elbow

¹The University of Queensland, School of Biomedical Sciences, St Lucia, Australia. ²The University of Queensland, School of Health and Rehabilitation Sciences: Physiotherapy, St Lucia, Australia. ³Menzies Health Institute Queensland, Griffith University, Gold Coast, Australia. No financial support was received for this manuscript. The authors certify that they have no affiliations with or financial involvement in any organization or entity with a direct financial interest in the subject matter or materials discussed in the article. Address correspondence to Dr Bill Vicenzino, School of Health and Rehabilitation Sciences, Department of Physiotherapy, The University of Queensland, Building 84A, St Lucia QLD 4072 Australia. E-mail: b.vicenzino@uq.edu.au ● Copyright ©2015 *Journal of Orthopaedic & Sports Physical Therapy*®

PATHOPHYSIOLOGY

THE PATHOPHYSIOLOGY OF LET IS multidimensional, and we have previously proposed a model that suggests that tendon cellular and matrix changes may be accompanied by alterations in nociceptive processing and impairments in sensory and motor function.²⁷ Recent studies have provided support for some aspects of this model,^{47,67} although the relationships between model components require greater exploration. There is strong evidence to suggest discordance between clinical severity and tendon pathology in patients with tendinopathy.^{34,46} Thus, it is inadequate for researchers and clinicians to concentrate on local tendon pathology to the exclusion of nervous system-mediated phenomena, physical functioning, and possibly psychological factors when diagnosing and managing patients with LET.

The histological features of LET are similar to those of other common tendinopathies and include increased cellularity, an accumulation of ground substance, collagen disorganization, and neurovascular ingrowth.⁶¹ The most common sites of focal degeneration are the deep and anterior fibers of the extensor carpi radialis brevis (ECRB) component of the common extensor tendon origin.^{7,20} Anatomical studies have shown that the ECRB tendon merges imperceptibly with the lateral collateral ligament (LCL), which in turn fuses with the annular ligament of the proximal radioulnar joint.⁷⁰ Consequently, considerable load sharing takes place between these structures and may explain progressive involvement of the LCL in more severe clinical presentations of LET.¹⁵

CLINICAL EXAMINATION

THE DIAGNOSIS OF LET IS ESSENTIALLY based on a clinical examination that aims to provoke pain in the affected tendon by loading. The physical examination should reproduce pain in the area of the lateral epicondyle in

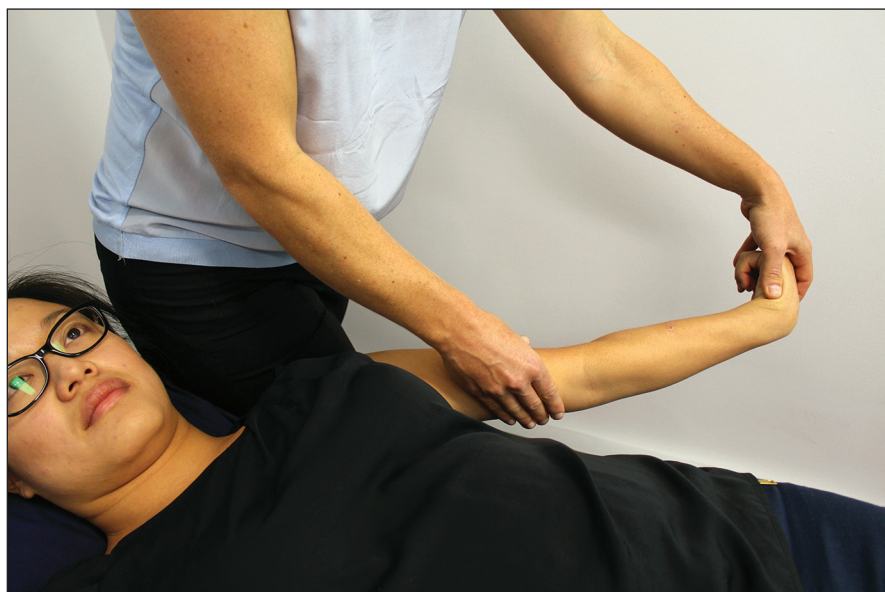

FIGURE 1. Radial nerve neurodynamic testing is performed by placing the upper limb in the following series of positions: gentle shoulder girdle depression, elbow extension, shoulder internal rotation, forearm pronation, wrist and finger flexion, shoulder abduction. A positive test result (indicating mechanosensitivity of the radial nerve) reproduces the patient's lateral elbow pain, which is altered with a sensitization maneuver, such as cervical lateral flexion or scapular elevation.

at least 1 of 3 ways: palpation of the lateral epicondyle; resisted extension of the wrist, index finger, or middle finger; and having the patient grip an object. A more comprehensive physical examination may be necessary to identify (or rule out) coexisting pathologies or other reasons for their pain.

Elbow, wrist, and forearm range of motion, as well as accessory motion of the radioulnar, radiohumeral, and humeroulnar joints, should be examined to identify any articular or musculotendinous restriction. In patients whose symptoms are suggestive of elbow instability (eg, clicking, loss of control, or difficulty with pushing up with the forearm supinated), several clinical tests are available to determine the presence or absence of the condition, including the posterolateral rotary drawer test⁷⁵ and tabletop relocation test.⁵ However, signs of instability on physical examination are commonly subtle and may need to be combined with results of imaging.⁵⁴

Evaluation of the cervical and thoracic spine and radial nerve function should also be a priority, particularly when there

is concomitant neck pain or diffuse arm pain or paresthesia. Reproduction of lateral elbow pain during manual palpation and/or active, passive, or combined movements of the cervical spine should raise suspicion of radicular or referred pain.¹¹⁴ Increased sensitivity of the radial nerve to mechanical stimuli may be evaluated by neurodynamic testing and palpation of the nerve along its length.⁹⁸ Radial nerve neurodynamic testing may be performed by moving the upper limb in the following sequence of movements: gentle shoulder girdle depression, elbow extension, shoulder internal rotation, forearm pronation, wrist and finger flexion, followed by shoulder abduction (**FIGURE 1**).^{16,24} A positive test requires reproduction of the patient's lateral elbow pain and alteration of symptoms by a sensitization maneuver, such as cervical lateral flexion or scapular elevation.²⁴ Further testing of afferent or efferent nerve function through neurological examination may be indicated if symptoms suggest sensory or motor loss.

Analysis of posture and movement within the whole kinetic chain is recom-

mended³ to identify potential risk factors that may be modifiable through rehabilitation. Insights gained from such analysis, along with evaluation of functional tasks undertaken in occupational and sport-specific activities, as well as sensory and motor function testing, will provide direction in the planning of management of the condition and the patient.

OUTCOME MEASURES

FOR GREATER CONSENSUS AND STANDARDIZATION between research trials and clinical practice, we recommend the pain-free grip test and the Patient-Rated Tennis Elbow Evaluation (PRTEE) as outcome measures. The pain-free grip test is a reliable, valid, and sensitive measure of physical impairment in LET.¹⁰⁶ A dynamometer is used to measure the grip force applied to the point of onset of pain.⁶⁶ Most protocols recommend performing the test with the elbow in relaxed extension and the forearm in pronation, repeating the test 3 times at 1-minute intervals, and comparing the average of these 3 measurements between the affected and unaffected sides. An alternative testing position with the elbow flexed to 90° and the forearm in neutral rotation can also be used.⁶⁶ The pain-free grip test is preferable to a measurement of maximal strength, which is not always impaired and is likely to exacerbate the pain, which may outlast the testing session.¹³

The PRTEE is a reliable, validated measure of pain and disability.^{71,94} It consists of 15 questions, 5 related to pain and 10 related to functional limitation during daily activities, work, and sport. Both subscales contribute equally to the total score, which ranges from 0 (no pain or disability) to 100 (worst possible pain and disability). In a previous cluster analysis, scores greater than 54 were considered to represent severe pain and disability, and scores less than 33 were considered to reflect mild pain and disability,²⁸ although validation of such cutoffs is necessary. Study of minimal

clinically important differences in total PRTEE scores⁸⁶ suggests that a reduction of at least 11 points or an improvement of 37% over baseline score indicates substantial improvement.⁸⁶

The Patient-Specific Functional Scale (PSFS) is another valid, reliable, and responsive outcome measure that may be used to measure progress in individual patients with upper extremity problems.⁴⁸ Patients nominate 3 to 5 activities that they are having difficulty performing because of their problem and rate these activities on an 11-point scale, where 0 is unable to perform the activity and 10 is able to perform the activity at preinjury level. A minimum clinically important difference of 1.2 is reported for the PSFS.⁴⁸

DIAGNOSTIC IMAGING

ULTRASOUND AND MAGNETIC RESONANCE imaging (MRI) demonstrate high sensitivity, but limited specificity, in detecting structural abnormalities in tendinopathies,^{34,46,79} including tendon thickening and focal areas of hypoechogenicity (ultrasound) or increased signal intensity (MRI). Meta-analysis of MRI studies found signal changes in 90% of affected and 50% of unaffected tendons.⁷⁹ Similarly, diagnostic ultrasound by an examiner blinded to status found tendinopathic changes in 90% of patients with LET and 53% of asymptomatic controls.⁴⁶ An exception was disruption of fibrils within the common extensor tendon, which showed 100% probability of LET.⁴⁶ Most studies find a lack of association between the severity of tendon changes and symptoms in both LET^{71,117} and other chronic tendinopathies.⁵⁷ However, the presence of an LCL tear and the size of any intrasubstance tendon tear detected by ultrasound were significantly associated with poorer prognosis in patients with LET.¹⁸

While changes on imaging that are apparent in both affected and unaffected limbs require cautious interpretation, negative ultrasound findings can be used to confidently rule out LET as a diagno-

sis^{34,46} and prompt the clinician to consider other causes of elbow pain. If the patient reports clicking or locking, computed tomography, MRI, or magnetic resonance arthrography may be used to detect other pathologies, such as loose bodies, articular cartilage damage, ligament injury, or elbow synovial fold (plica) syndrome.^{39,60} Ultrasound may also be useful in diagnosing radial or posterior interosseous nerve compression, by detecting swelling and hypoechogenicity of the nerve or identifying secondary causes such as cysts.^{59,60} Nerve conduction testing may be used to detect slowed conduction velocity of an entrapped posterior interosseous nerve.⁵⁶

DIFFERENTIAL DIAGNOSIS

THE TABLE LISTS OTHER POTENTIAL sources of lateral elbow pain, many of which lack universally accepted definitions and diagnostic criteria.^{44,51} The lack of clearly distinct diagnostic criteria may underpin differences in reported prevalence rates and prognosis of these conditions between studies. Included in this list is nonspecific arm pain, a diagnosis often reached by exclusion of other specific conditions.^{44,51} There is little consensus regarding diagnostic criteria for radial tunnel syndrome, which shares similar clinical features with LET and may occur in combination with LET.⁶⁰ In contrast, objective (motor) dysfunction of the musculature innervated by the posterior interosseous nerve should be used as a requirement for a diagnosis of posterior interosseous nerve entrapment.⁹⁵ Early identification of the condition and referral of these patients to a specialist are important, as they may require surgical decompression to avoid permanent injury.⁵⁶ It should also be recognized that LET may present as an isolated entity or coexist with other pathologies, making clinical differentiation difficult. For example, patients with chronic LET who sustain an acute injury with worsening of symptoms may have developed additional LCL injury.^{35,92}

TABLE

DIFFERENTIAL DIAGNOSES OF LATERAL ELBOW TENDINOPATHY

Differential Diagnoses	Key Features
Local arthritis ⁷⁸	<ul style="list-style-type: none"> Resting pain, joint stiffness Pain and restricted motion due to impingement at the extremes of flexion and extension, or in advanced stages, throughout the arc of motion History of trauma or of heavy use (eg, manual laborers, weight lifters, throwing athletes)
Intra-articular pathology ⁶⁰	<ul style="list-style-type: none"> Clicking or catching with elbow motion MRI or arthroscopy may detect cartilage defects or intra-articular bodies
Radiocapitellar pathology ^{60,96}	<ul style="list-style-type: none"> Commonly seen in younger athletes following trauma or associated with medial elbow instability (eg, in throwing athlete) Tenderness posterior to the lateral epicondyle centered over the posterior radiocapitellar joint Painful click or snap with terminal elbow extension and forearm supination; may show restriction of elbow extension Ultrasound, MRI, or arthroscopy may demonstrate inflammation or hypertrophic synovial plica or radiocapitellar chondromalacia
Radial tunnel syndrome ⁶⁰	<ul style="list-style-type: none"> Diffuse aching pain over wrist extensor muscles, possibly radiating to the dorsal aspect of the hand, or sharp, shooting pain along the dorsal forearm region. Pain often worse at night Rarely, sensory or motor changes Pain may be increased by resisted supination, neurodynamic tests, and/or nerve palpation Electrodiagnostic testing often inconclusive Ultrasound may show nerve compression
Posterior interosseous nerve entrapment ⁹⁵	<ul style="list-style-type: none"> Neurological deficit: weakness of posterior interosseous nerve innervated muscles (finger and thumb extensors and abductor pollicis longus) Electrodiagnostic testing shows abnormal radial nerve conduction in some cases Pain (when present) is usually in distal forearm and wrist and may refer proximally
Cervical referred pain or radiculopathy	<ul style="list-style-type: none"> Radiation of pain from cervical spine, reproduced by palpation and/or active or passive movements of the cervical spine Focal motor, reflex, or sensory changes associated with the affected nerve
Posterolateral rotatory instability ⁴	<ul style="list-style-type: none"> History of acute trauma (eg, fall onto the outstretched hand); rarely an overuse injury Painful snapping, clicking, or feeling of instability during elbow flexion/extension with forearm supinated
Nonspecific arm pain ^{44,51}	<ul style="list-style-type: none"> Diffuse forearm pain not associated with any particular structure

Abbreviation: MRI, magnetic resonance imaging.

FACTORS AFFECTING PROGNOSIS

THERE IS NO UNIVERSALLY EFFECTIVE treatment for all patients presenting with LET. Heterogeneity in clinical presentation and pathophysiology suggests that interventions are more likely to be successful if individually tailored. Based on current evidence and expert opinion, we propose that the following 6 factors should be considered when designing a rehabilitation program.

Tendon Pathology

A continuum of tendon changes may be found in patients with tendinopathy, ranging from a homogeneous, noninflammatory, diffuse increase in cellularity and ground substance (“reactive tendinopathy”) to focal areas of collagen

disorganization and neurovascular ingrowth (“degenerative tendinopathy”).²¹ Specifically for LET, as discussed above, tendon and ligament disruptions are also reported in more advanced cases of LET,^{15,18,87} their presence and size linked with poorer prognosis.¹⁸

Cook and Purdam²¹ suggest that rehabilitation should differ between stages of tendinopathy, although the authors recognize that clinical differentiation is difficult. Reactive tendinopathy, which commonly occurs in response to unaccustomed or increased activity, requires reduced or modified loads to give the tendon time to recover. In contrast, interventions such as eccentric exercise and prolotherapy injections, which aim to stimulate increased production of collagen or ground substance and restructure tendon matrix, might be more appro-

priate for degenerative tendinopathy.²¹ Patients with LET and a large intrasubstance tear or LCL tear, who are more likely to fail nonoperative treatment, including 6 months of eccentric loading, may require reconstructive surgery.⁵⁴

Severity of Pain and Disability

Lateral elbow tendinopathy may also present as a continuum of symptoms ranging from relatively mild yet persistent annoyances during daily activities to severe and significant symptoms limiting all facets of life.¹²⁰ There is strong evidence that patients with greater baseline pain and disability have a poorer long-term prognosis,^{25,102} warranting early intervention for this at-risk population. Furthermore, patients with severe symptoms (PRTEE scores greater than 54) have been found to display more pronounced sensory dis-

turbances that may be targeted by different pharmacological therapies (described below).²⁸ Effective pain management may be achieved by rest, use of an orthotic wrist splint, counterforce elbow strap, or taping (**FIGURE 2**), the latter helpful for patients with resting or night pain.^{109,110} Where physical modalities (eg, exercise and manual therapy) are used, these should be initiated cautiously, performed below the individual's pain threshold, and progressed more slowly to avoid provoking or sustaining central sensitization.⁷⁴

Central Sensitization

Central sensitization is implicated in the pathophysiology of LET and several other chronic musculoskeletal conditions, such as whiplash-associated disorders and fibromyalgia.^{53,73,113} In individuals with LET, there is evidence of heightened nociceptive withdrawal reflex⁶⁷ and widespread mechanical hyperalgesia.^{28,36,37} A subgroup of patients reporting severe levels of pain and disability displayed cold hyperalgesia (mean, 13.7°C),²⁸ while cold pain threshold was an independent predictor of short- and long-term prognosis in untreated individuals with LET.²⁵ This is consistent with other musculoskeletal pain conditions such as whiplash-associated disorder, in which cold pain thresholds greater than 13°C have been linked to an increased risk of persistent pain.¹⁰⁵ Recent studies show that a clinical ice pain test is correlated with quantitative measures, enabling clinicians to examine pain sensitivity in the absence of expensive equipment.⁹¹ Pain intensity of more than 5/10, after 10 seconds of ice application indicated 90% likelihood of cold hyperalgesia.⁶⁹

An understanding of the contribution of central sensitization to the development and persistence of pain in LET may lead to more appropriate and targeted treatments. Clinical assessment that identifies increased responsiveness to a variety of physical and emotional stimuli, heightened response to neurodynamic testing, or expansion of symptoms to sites outside the injured area may provide the clinician with important clues for central sensitization.⁷⁴

Treatments for management of central sensitization in patients with musculoskeletal pain are described by Nijs and colleagues.⁷⁴ The results of a systematic review indicate that cervical spine manual therapy reduces mechanical hyperalgesia at remote sites in people with and without musculoskeletal pain, suggesting a potential effect on central sensitization.³⁰ Neural mobilization exercises might also be suitable for addressing central sensitization processes, including enhanced sensory hypersensitivity in response to repeated stimuli.⁶ Motor control and isometric exercises may be appropriate, as well as exercise of nonpainful regions.⁷²

Concomitant Neck or Shoulder Pain

Neck pain is more common in patients with LET than in an age-matched healthy population.⁸ Physical impairments have also been demonstrated on manual examination of C4-C7 segmental levels in patients with relatively localized symptoms of LET.²⁴ Moreover, self-report of shoulder or neck pain in patients with LET presenting to general practice was indicative of poorer short- or long-term prognosis, respectively.¹⁰² Associated musculoskeletal comorbidities may be addressed during rehabilitation using manual therapy and exercise.

Associated Neuromuscular Impairments

Impairment in sensory and motor function is commonly seen in patients with LET and may persist beyond resolution of local tendon symptoms.^{2,12} In addition to reduced pain-free grip force, affected individuals commonly grip with a more flexed wrist position¹³ and display weakness of the short wrist extensors (ECRB) but not the finger extensors.³ Widespread muscle weakness in the affected limb³ and bilateral deficits in reaction time and speed of movement¹³ are also found in patients with unilateral LET. Recent investigation of the motor representation of wrist extensor muscles using transcranial magnetic stimulation indicates that cortical organization may be maladaptive in patients with LET.⁹⁷ Failure to recognize and address

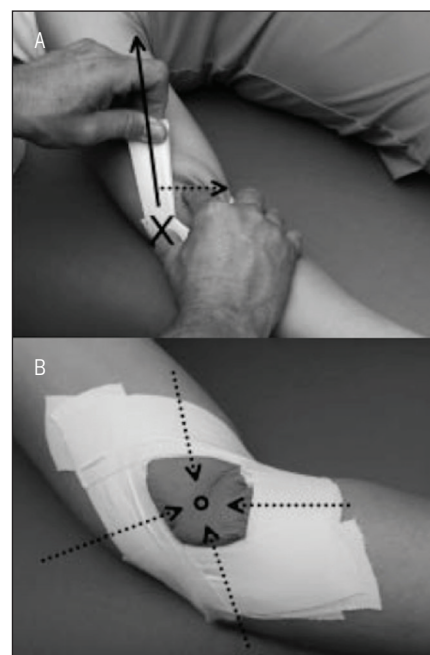


FIGURE 2. Diamond taping is applied using rigid tape, with the goal to unload painful tissues at the common extensor tendon origin. The elbow is first placed in a position of comfort, then: (A) starting from the anchor point (x), tape is tensioned in a proximal direction (solid arrow), while the skin is moved toward the inside of the diamond (broken-line arrow). (B) Note the orange peel effect on the skin within the diamond tape, resulting from unloading of tissues toward the site of pain (circle). Reproduced with permission.¹¹⁰

problems with motor control, strength, and endurance may be one explanation for persistence or recurrence of symptoms.

Work-Related and Psychosocial Factors

Several work-related physical and psychosocial factors have been associated with an increased occurrence of LET^{42,108} and poorer overall prognosis after 1 year.⁴² These include handling tools, handling heavy loads, and repetitive movements, as well as low job control. Individuals adopting nonneutral wrist postures during work activity have been shown to have a poor prognosis for LET.⁹⁹ Work absenteeism is documented in 5% of affected working adults, with a median duration of 29 days in the previous 12-month time period.¹¹⁵ Modification of physical factors could reduce the risk or improve the prognosis of LET. In the workplace, ergonomic modifications

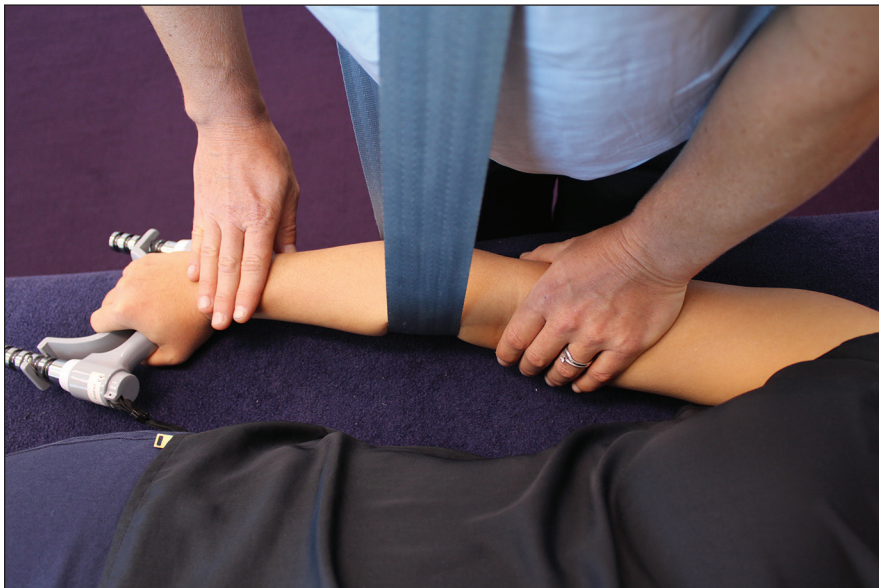

FIGURE 3. Lateral elbow mobilization with movement. This technique consists of applying and sustaining a lateral humeroulnar accessory glide while the patient performs (and relaxes) their painful action (eg, gripping). If significant improvement in pain-free grip is observed, repeat the technique for a total of 6 to 10 repetitions. A belt may be used to assist with the glide.

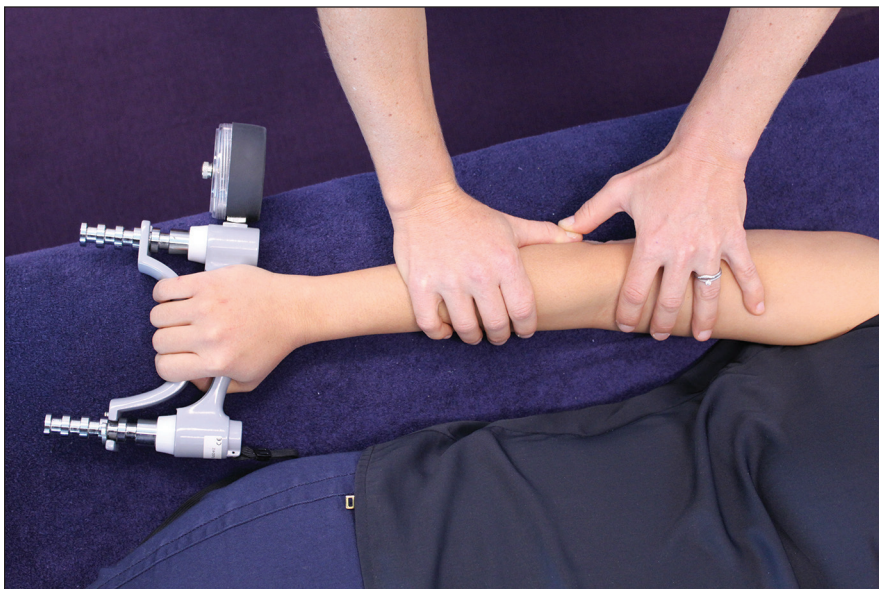

FIGURE 4. Radial head posteroanterior mobilization with movement. This technique consists of applying and sustaining a posterior-to-anterior glide over the radial head while the patient performs (and relaxes) the painful action (eg, gripping). If significant improvement in pain-free grip is observed, repeat the technique 6 to 10 times.

should focus on minimizing work tasks requiring deviated wrist postures, forceful exertions, and highly repetitive movements, and adequate rest and recovery periods should be allowed.⁹⁹

In contrast, the role of psychological factors in the development and persistence

of pain in patients with LET is conflicting. Higher anxiety and depression were found in 2 small cross-sectional studies,^{1,40} but not in a larger study of patients with LET. Longitudinal study of patients with LET did not find any association between psychological factors and prognosis.²⁵ How-

ever, another study found that depression was associated with a greater use of medical resources by patients when a “wait-and-see” approach was recommended by their primary practitioner.⁶⁵

POTENTIAL INTERVENTIONS

Pharmacotherapy

THERE IS CONFLICTING EVIDENCE FOR the role of oral nonsteroidal anti-inflammatory medication in the management of LET.⁸⁰ Based on findings of tendon cellular and matrix inhibition with indomethacin and naproxen, it has been speculated that these drugs may be more appropriate for patients with reactive rather than degenerative tendinopathy.²¹ There is strong evidence that corticosteroid medication provides short-term relief of pain but leads to worse outcomes after 6 and 12 months compared to either a wait-and-see approach or physical therapy management, with substantial recurrence rates.²⁶ More recent research showed that adding a multimodal physical therapy program (elbow mobilization and resistance exercise) did not ameliorate the late delay in recovery or recurrence observed after a single corticosteroid injection.²² For these reasons, we do not advocate corticosteroid injection as a first-line intervention for LET. Other more centrally acting analgesics, such as antidepressant or antiepileptic drugs, may be appropriate for patients with severe pain where central sensitization is suspected, although no studies have been conducted in this population to date. A meta-analysis found strong evidence for antidepressant medication in the relief of pain in patients with fibromyalgia, another condition associated with central sensitization.⁴⁵ Prolotherapy and nitric oxide patches have demonstrated long-term beneficial effects in patients with chronic (greater than 3 months) LET.^{76,88} Their efficacy may depend on appropriate physical stimulus, based on evidence of a lack of effect of nitric oxide patches when combined with stretching only.⁷⁷ Despite large clinical

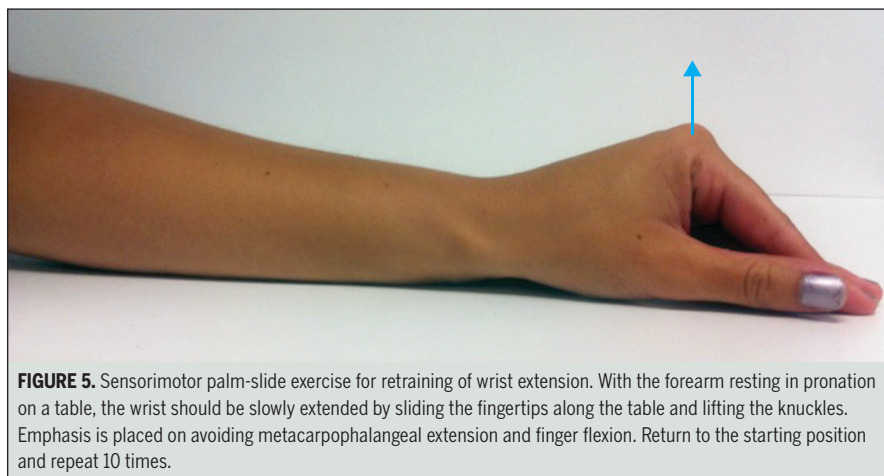

FIGURE 5. Sensorimotor palm-slide exercise for retraining of wrist extension. With the forearm resting in pronation on a table, the wrist should be slowly extended by sliding the fingertips along the table and lifting the knuckles. Emphasis is placed on avoiding metacarpophalangeal extension and finger flexion. Return to the starting position and repeat 10 times.

FIGURE 6. Wrist extension exercise can be performed over the edge of a table with elastic tubing or free weights. Isometric holds (30-60 seconds in duration) are advocated for reactive or irritable tendinopathy, while concentric and eccentric actions should be performed slowly (4 seconds for each direction), completing 2 to 3 sets of 10 repetitions for patients with less irritable or degenerative tendinopathy. Emphasis is placed on maintaining neutral radial-ulnar deviation of the wrist (by aligning the middle metacarpal bone with the long axis of the forearm). Progression may be achieved by increasing load or performing the exercises with greater elbow extension.

interest, there is growing evidence that injection of autologous blood or platelet-rich blood products is not effective in treating LET.^{32,62}

Manual Therapy

There is moderate evidence for the immediate effects of several manual therapy techniques on pain and grip strength^{81,111} and for short-term clinical benefits when used in conjunction with graduated exercise.⁵⁸ The ulnar-humeral lateral glide (FIGURE 3) and radial head posteroanterior glide (FIGURE 4) are 2 techniques that can be used following the approach known as Mulligan mobilization with movement, where the patient performs the pain-producing movement in conjunction with sustained mobilization.¹¹² These treatment techniques are to be used when they produce substantial immediate improvement (eg, 50%) in pain and impairment (eg, pain-free grip force). There is also moderate evidence that manual therapy techniques targeting the cervical and thoracic regions provide additional clinical benefits beyond local elbow treatment alone in patients with LET and coexisting cervical or thoracic spine impairment.¹⁹

Exercise Therapy

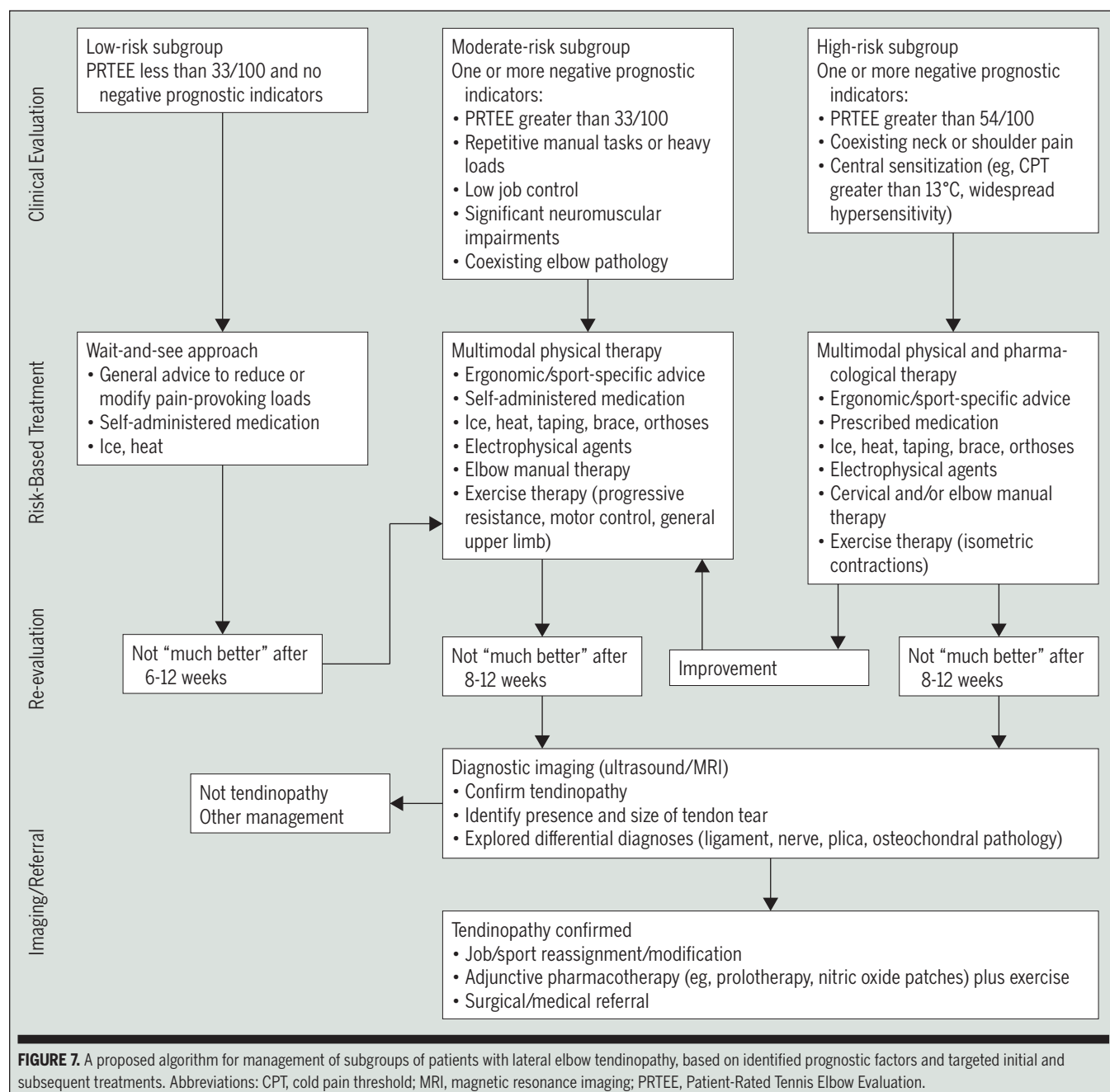
Exercise is central to management of many patients with LET, with evidence of benefits from exercise alone^{31,83,85,107} or as a part of a multimodal physical therapy regime.^{10,22} In patients with chronic LET,

exercise has been shown to lead to greater and faster regression of pain,⁸³ less sick leave, fewer medical consultations, and increased work ability.⁸⁴ Despite clear benefits, the most optimal exercise intensity, duration, frequency, and type of load for rehabilitation of LET have not been established.⁸⁹ General guidelines recommend application of gradually increasing resistance, focusing on the extensor muscles of the wrist.¹⁰⁴ Some studies favor eccentric over concentric exercise,^{82,89} while others indicate no differences between concentric or combined concentric/eccentric programs.⁶⁸ There is also conflicting opinion on whether pain should be provoked during exercise. Some insist that pain should be avoided during exercise,^{31,109} while others suggest that pain during exercise of less than 5 on a 10-cm visual analog scale is permissible.^{38,100}

Given the heterogeneity of the clinical presentation and pathology of LET, it is likely that optimal modes and doses of exercise differ between patients with different stages or severity levels of tendinopathy,²¹ as well as different premorbid functional demands. Isometric exercises of the wrist extensor muscles have a role, based on their wrist-stabilizing function in many activities.¹⁰³ Although their effect on pain in patients with LET requires further study, isometric contractions were shown to produce a greater analgesic effect than isotonic exercise in patients with patellar tendinopathy.⁹³ For patients with

reactive tendinopathy or irritable symptoms, gentle, pain-free isometric contractions of 30 to 60 seconds in duration, performed daily, with the wrist in 20° to 30° of wrist extension and elbow in 90° of flexion, may be more appropriate than eccentric exercise, which tends to aggravate pain. Progression may also be achieved by increasing the duration of contraction (up to 90 seconds) and by increasing the load (through a free weight or resistance tubing). Exercises should also address motor control impairments,^{23,85} such as dissociation of wrist from finger extension (FIGURE 5) and retraining of wrist alignment during gripping.

Concentric and/or eccentric exercise of the wrist extensors is advocated for patients with degenerative-stage tendinopathy,²¹ commencing with the elbow in flexion and restricting end-of-range wrist flexion, when the ECRB tendon may be exposed to greater compression and more pain^{33,90} (FIGURE 6). A similar approach restricting full ankle dorsiflexion during eccentric exercises was more successful for patients with insertional Achilles tendi-



nopathy.⁵² In the degenerative stage, pain up to 3/10 (where 10 is the worst imaginable pain) may be acceptable during exercise, but not the following morning. Strengthening of muscles of the rotator cuff and scapula should be included in rehabilitation, based on previously identified deficits.² For athletes involved in throwing or racquet-based sports, plyometric exercises may be needed to im-

prove tolerance to elastic loading during explosive muscular contractions.¹¹⁹

Education

Patients with LET can be reassured that, most likely, the condition will resolve gradually with adequate rest and time. Instruction to avoid pain-provoking activities (eg, by not lifting with a pronated forearm) and discussion about rest and

recovery from high loads are particularly important in rehabilitation of reactive tendinopathy. Ergonomic advice may focus on minimizing work tasks requiring deviated wrist postures, forceful exertions, and highly repetitive movements. Patients should be encouraged to gradually reintroduce more strenuous tasks and to reduce tendon load if recurrence is experienced.

Proposed Treatment Guidelines

Decision making regarding allocation and prioritization of treatment for the entire spectrum of patients with LET is currently inconsistent. Based on prognostic factors collated in this article, we propose an algorithm that identifies 3 subgroups and links these groups with individually targeted, initial and subsequent treatment strategies (FIGURE 7). We recognize that other factors, including patient preference, cost, or resource availability, may also direct the clinician to particular interventions. It has been demonstrated that patients with LET assigned to a wait-and-see approach sought significantly more not-per-protocol treatments than those assigned to physical therapy.^{10,49,118} In a recent economic analysis, a single corticosteroid injection, 8 sessions of multimodal physical therapy, and a combination of the two were each compared over 1 year with a placebo injection.²⁹ The study concluded that the multimodal program (of elbow manual therapy and exercise) was highly likely to be cost-effective, while the cost-effectiveness of corticosteroid injection was more uncertain. Ultimately, the clinical utility and cost-effectiveness of the proposed algorithm depend on testing through clinical trials, such as those conducted for low back pain.^{49,118}

We propose that low-risk patients with low pain severity and no negative prognostic indicators may be suitable for advice and self-administered pain medication, consistent with a wait-and-see policy. This approach may also be adopted when there is reason to believe the patient will not adhere to an exercise program and the patient is not continually exposed to activities that will perpetuate symptoms of LET. If meaningful improvement is not observed after 6 to 12 weeks or if symptoms worsen, multimodal physical therapy should be initiated.

For high-risk patients with severe pain and disability (eg, PRTEE score greater than 54/100), concomitant neck pain, or suspected central sensitization (eg, cold pain threshold greater than 13°C, wide-

spread hypersensitivity to multiple stimuli), a combination of physical therapy and pharmacotherapy is recommended. Pain management should be the primary goal of treatment, including options such as medication, manual therapy, taping, or orthoses. Isometric exercise may be commenced at loads below pain threshold, with progression to concentric and eccentric programs when symptoms become less irritable.

For the remaining population, herein described as moderate risk, a multimodal physical therapy regime is recommended as a first-line management, with the goal of faster reduction of pain and recovery of function. We suggest a minimum of 8 to 12 weeks of physical rehabilitation, individually prescribed to target specific physical impairments, including progressive strengthening and endurance exercise and elbow manual therapy, consistent with what has been used in previous studies of LET.^{10,22}

Based on this model, diagnostic imaging is reserved for cases recalcitrant to physical therapy. If findings on imaging are consistent with the presence of tendinopathy, the patient may be counseled regarding other second-line interventions, such as prolotherapy injections or nitric oxide patches. Patients with severe pain with LCL or tendon tears on imaging may require early referral to an orthopaedic surgeon.

Monitoring of patient recovery may be achieved using repeated use of the PRTEE or PSFS questionnaires.^{48,86} Time frames and thresholds for recovery are provided as a guide for clinicians.

CONCLUSION

UNRAVELING THE COMPLEX ETIOLOGY and mechanisms underlying the persistence of pain in patients with LET is challenging. We highlight several prognostic factors, including central sensitization, local structural damage (eg, tendon and ligament tears), and comorbid musculoskeletal pain, and discuss their significance in terms of design of physical rehabilitation programs. We propose

a preliminary algorithm based on risk of poor outcomes as a means of guiding clinical decision making regarding treatment options for patients with LET. ●

REFERENCES

1. Alizadehkhayat O, Fisher AC, Kemp GJ, Frostick SP. Pain, functional disability, and psychologic status in tennis elbow. *Clin J Pain*. 2007;23:482-489. <http://dx.doi.org/10.1097/AJP0b013e31805f70fa>
2. Alizadehkhayat O, Fisher AC, Kemp GJ, Vishwanathan K, Frostick SP. Assessment of functional recovery in tennis elbow. *J Electromyogr Kinesiol*. 2009;19:631-638. <http://dx.doi.org/10.1016/j.jelekin.2008.01.008>
3. Alizadehkhayat O, Fisher AC, Kemp GJ, Vishwanathan K, Frostick SP. Upper limb muscle imbalance in tennis elbow: a functional and electromyographic assessment. *J Orthop Res*. 2007;25:1651-1657. <http://dx.doi.org/10.1002/jor.20458>
4. Anakwenze OA, Kancharla VK, Iyengar J, Ahmad CS, Levine WN. Posterolateral rotatory instability of the elbow. *Am J Sports Med*. 2014;42:485-491. <http://dx.doi.org/10.1177/0363546513494579>
5. Arvind CH, Hargreaves DG. Table top relocation test—new clinical test for posterolateral rotatory instability of the elbow. *J Shoulder Elbow Surg*. 2006;15:500-501. <http://dx.doi.org/10.1016/j.jse.2005.11.014>
6. Beneciuk JM, Bishop MD, George SZ. Effects of upper extremity neural mobilization on thermal pain sensitivity: a sham-controlled study in asymptomatic participants. *J Orthop Sports Phys Ther*. 2009;39:428-438. <http://dx.doi.org/10.2519/jospt.2009.2954>
7. Benjamin M, Toumi H, Ralphs JR, Bydder G, Best TM, Milz S. Where tendons and ligaments meet bone: attachment sites ('entheses') in relation to exercise and/or mechanical load. *J Anat*. 2006;208:471-490. <http://dx.doi.org/10.1111/j.1469-7580.2006.00540.x>
8. Berglund KM, Persson BH, Denison E. Prevalence of pain and dysfunction in the cervical and thoracic spine in persons with and without lateral elbow pain. *Man Ther*. 2008;13:295-299. <http://dx.doi.org/10.1016/j.math.2007.01.015>
9. Binder AI, Hazleman BL. Lateral humeral epicondylitis—a study of natural history and the effect of conservative therapy. *Br J Rheumatol*. 1983;22:73-76. <http://dx.doi.org/10.1093/rheumatology/22.2.73>
10. Bisset L, Beller E, Jull G, Brooks P, Darnell R, Vicenzino B. Mobilisation with movement and exercise, corticosteroid injection, or wait and see for tennis elbow: randomised trial. *BMJ*. 2006;333:939. <http://dx.doi.org/10.1136/bmj.38961.584653.AE>
11. Bisset L, Smidt N, Van der Windt DA, et al. Conservative treatments for tennis elbow—do

- subgroups of patients respond differently? *Rheumatology (Oxford)*. 2007;46:1601-1605. <http://dx.doi.org/10.1093/rheumatology/kem192>
12. Bisset LM, Coppieters MW, Vicenzino B. Sensorimotor deficits remain despite resolution of symptoms using conservative treatment in patients with tennis elbow: a randomized controlled trial. *Arch Phys Med Rehabil*. 2009;90:1-8. <http://dx.doi.org/10.1016/j.apmr.2008.06.031>
 13. Bisset LM, Russell T, Bradley S, Ha B, Vicenzino BT. Bilateral sensorimotor abnormalities in unilateral lateral epicondylalgia. *Arch Phys Med Rehabil*. 2006;87:490-495. <http://dx.doi.org/10.1016/j.apmr.2005.11.029>
 14. Bot SD, van der Waal JM, Terwee CB, van der Windt DA, Bouter LM, Dekker J. Course and prognosis of elbow complaints: a cohort study in general practice. *Ann Rheum Dis*. 2005;64:1331-1336. <http://dx.doi.org/10.1136/ard.2004.030320>
 15. Bredella MA, Tirman PF, Fritz RC, Feller JF, Wischer TK, Genant HK. MR imaging findings of lateral ulnar collateral ligament abnormalities in patients with lateral epicondylitis. *AJR Am J Roentgenol*. 1999;173:1379-1382. <http://dx.doi.org/10.2214/ajr.173.5.10541124>
 16. Butler DS, Jones MA. *Mobilisation of the Nervous System*. London, UK: Churchill Livingstone; 1991.
 17. Chourasia AO, Buhr KA, Rabago DP, et al. Relationships between biomechanics, tendon pathology, and function in individuals with lateral epicondylitis. *J Orthop Sports Phys Ther*. 2013;43:368-378. <http://dx.doi.org/10.2519/jospt.2013.4411>
 18. Clarke AW, Ahmad M, Curtis M, Connell DA. Lateral elbow tendinopathy: correlation of ultrasound findings with pain and functional disability. *Am J Sports Med*. 2010;38:1209-1214. <http://dx.doi.org/10.1177/0363546509359066>
 19. Cleland JA, Flynn TW, Palmer JA. Incorporation of manual therapy directed at the cervicothoracic spine in patients with lateral epicondylalgia: a pilot clinical trial. *J Man Manip Ther*. 2005;13:143-151. <http://dx.doi.org/10.1179/106698105790824932>
 20. Connell D, Burke F, Coombes P, et al. Sonographic examination of lateral epicondylitis. *AJR Am J Roentgenol*. 2001;176:777-782. <http://dx.doi.org/10.2214/ajr.176.3.1760777>
 21. Cook JL, Purdam CR. Is tendon pathology a continuum? A pathology model to explain the clinical presentation of load-induced tendinopathy. *Br J Sports Med*. 2009;43:409-416. <http://dx.doi.org/10.1136/bjsm.2008.051193>
 22. Coombes BK, Bisset L, Brooks P, Khan A, Vicenzino B. Effect of corticosteroid injection, physiotherapy, or both on clinical outcomes in patients with unilateral lateral epicondylalgia: a randomized controlled trial. *JAMA*. 2013;309:461-469. <http://dx.doi.org/10.1001/jama.2013.129>
 23. Coombes BK, Bisset L, Connelly LB, Brooks P, Vicenzino B. Optimising corticosteroid injection for lateral epicondylalgia with the addition of physiotherapy: a protocol for a randomised control trial with placebo comparison. *BMC Musculoskelet Disord*. 2009;10:76. <http://dx.doi.org/10.1186/1471-2474-10-76>
 24. Coombes BK, Bisset L, Vicenzino B. Bilateral cervical dysfunction in patients with unilateral lateral epicondylalgia without concomitant cervical or upper limb symptoms: a cross-sectional case-control study. *J Manipulative Physiol Ther*. 2014;37:79-86. <http://dx.doi.org/10.1016/j.jmpt.2013.12.005>
 25. Coombes BK, Bisset L, Vicenzino B. Cold hyperalgesia associated with poorer prognosis in lateral epicondylalgia: a 1-year prognostic study of physical and psychological factors. *Clin J Pain*. 2015;31:30-35. <http://dx.doi.org/10.1097/AJP.0000000000000078>
 26. Coombes BK, Bisset L, Vicenzino B. Efficacy and safety of corticosteroid injections and other injections for management of tendinopathy: a systematic review of randomised controlled trials. *Lancet*. 2010;376:1751-1767. [http://dx.doi.org/10.1016/S0140-6736\(10\)61160-9](http://dx.doi.org/10.1016/S0140-6736(10)61160-9)
 27. Coombes BK, Bisset L, Vicenzino B. A new integrative model of lateral epicondylalgia. *Br J Sports Med*. 2009;43:252-258. <http://dx.doi.org/10.1136/bjsm.2008.052738>
 28. Coombes BK, Bisset L, Vicenzino B. Thermal hyperalgesia distinguishes those with severe pain and disability in unilateral lateral epicondylalgia. *Clin J Pain*. 2012;28:595-601. <http://dx.doi.org/10.1097/AJP.0b013e31823dd333>
 29. Coombes BK, Connelly L, Bisset L, Vicenzino B. Economic evaluation favours physiotherapy but not corticosteroid injection as a first-line intervention for chronic lateral epicondylalgia: evidence from a randomised clinical trial. *Br J Sports Med*. In press. <http://dx.doi.org/10.1136/bjsports-2015-094729>
 30. Coronado RA, Gay CW, Bialosky JE, Carnaby GD, Bishop MD, George SZ. Changes in pain sensitivity following spinal manipulation: a systematic review and meta-analysis. *J Electromyogr Kinesiol*. 2012;22:752-767. <http://dx.doi.org/10.1016/j.jelekin.2011.12.013>
 31. Croisier JL, Foidart-Dessalle M, Tinant F, Crielaard JM, Forthomme B. An isokinetic eccentric programme for the management of chronic lateral epicondylar tendinopathy. *Br J Sports Med*. 2007;41:269-275. <http://dx.doi.org/10.1136/bjsm.2006.033324>
 32. de Vos RJ, van Veldhoven PL, Moen MH, Weir A, Tol JL, Maffulli N. Autologous growth factor injections in chronic tendinopathy: a systematic review. *Br Med Bull*. 2010;95:63-77. <http://dx.doi.org/10.1093/bmb/ldq006>
 33. Dorf ER, Chhabra AB, Golish SR, McGinty JL, Pannunzio ME. Effect of elbow position on grip strength in the evaluation of lateral epicondylitis. *J Hand Surg Am*. 2007;32:882-886. <http://dx.doi.org/10.1016/j.jhsa.2007.04.010>
 34. du Toit C, Stieler M, Saunders R, Bisset L, Vicenzino B. Diagnostic accuracy of power Doppler ultrasound in patients with chronic tennis elbow. *Br J Sports Med*. 2008;42:872-876. <http://dx.doi.org/10.1136/bjsm.2007.043901>
 35. Dzigan SS, Savoie FH, 3rd, Field LD, O'Brien MJ, You Z. Acute radial ulno-humeral ligament injury in patients with chronic lateral epicondylitis: an observational report. *J Shoulder Elbow Surg*. 2012;21:1651-1655. <http://dx.doi.org/10.1016/j.jse.2012.04.008>
 36. Fernández-Carnero J, Fernández-de-las-Peñas C, de la Llave-Rincón AI, Ge HY, Arendt-Nielsen L. Widespread mechanical pain hypersensitivity as sign of central sensitization in unilateral epicondylalgia: a blinded, controlled study. *Clin J Pain*. 2009;25:555-561. <http://dx.doi.org/10.1097/AJP.0b013e3181a68a040>
 37. Fernández-Carnero J, Fernández-de-las-Peñas C, Sterling M, Souvliis T, Arendt-Nielsen L, Vicenzino B. Exploration of the extent of somato-sensory impairment in patients with unilateral lateral epicondylalgia. *J Pain*. 2009;10:1179-1185. <http://dx.doi.org/10.1016/j.jpain.2009.04.015>
 38. Finestone HM, Rabinovitch DL. Tennis elbow no more: practical eccentric and concentric exercises to heal the pain. *Can Fam Physician*. 2008;54:1115-1116.
 39. Frick MA, Murthy NS. Imaging of the elbow: muscle and tendon injuries. *Semin Musculoskelet Radiol*. 2010;14:430-437. <http://dx.doi.org/10.1055/s-0030-1263258>
 40. Garnevall B, Rabey M, Edman G. Psychosocial and personality factors and physical measures in lateral epicondylalgia reveal two groups of "tennis elbow" patients, requiring different management. *Scand J Pain*. 2013;4:155-162. <http://dx.doi.org/10.1016/j.sjpain.2013.05.001>
 41. Gruchow HW, Pelletier D. An epidemiologic study of tennis elbow. Incidence, recurrence, and effectiveness of prevention strategies. *Am J Sports Med*. 1979;7:234-238.
 42. Haahr JP, Andersen JH. Prognostic factors in lateral epicondylitis: a randomized trial with one-year follow-up in 266 new cases treated with minimal occupational intervention or the usual approach in general practice. *Rheumatology (Oxford)*. 2003;42:1216-1225. <http://dx.doi.org/10.1093/rheumatology/keg360>
 43. Hamilton PG. The prevalence of humeral epicondylitis: a survey in general practice. *J R Coll Gen Pract*. 1986;36:464-465.
 44. Harrington JM, Carter JT, Birrell L, Gompertz D. Surveillance case definitions for work related upper limb pain syndromes. *Occup Environ Med*. 1998;55:264-271. <http://dx.doi.org/10.1136/oem.55.4.264>
 45. Häuser W, Bernardy K, Üçeyler N, Sommer C. Treatment of fibromyalgia syndrome with antidepressants: a meta-analysis. *JAMA*. 2009;301:198-209. <http://dx.doi.org/10.1001/jama.2008.944>
 46. Heales LJ, Broadhurst N, Mellor R, Hodges PW, Vicenzino B. Diagnostic ultrasound imaging for lateral epicondylalgia: a case-control study. *Med Sci Sports Exerc*. 2014;46:2070-2076. <http://dx.doi.org/10.1249/MSS.0000000000000345>
 47. Heales LJ, Lim EC, Hodges PW, Vicenzino B. Sensory and motor deficits exist on the non-injured side of patients with unilateral tendon pain and

disability—implications for central nervous system involvement: a systematic review with meta-analysis. *Br J Sports Med*. 2014;48:1400-1406. <http://dx.doi.org/10.1136/bjsports-2013-092535>

48. Hefford C, Abbott JH, Arnold R, Baxter GD. The Patient-Specific Functional Scale: validity, reliability, and responsiveness in patients with upper extremity musculoskeletal problems. *J Orthop Sports Phys Ther*. 2012;42:56-65. <http://dx.doi.org/10.2519/jospt.2012.3953>
49. Hill JC, Whitehurst DG, Lewis M, et al. Comparison of stratified primary care management for low back pain with current best practice (StarT Back): a randomised controlled trial. *Lancet*. 2011;378:1560-1571. [http://dx.doi.org/10.1016/S0140-6736\(11\)60937-9](http://dx.doi.org/10.1016/S0140-6736(11)60937-9)
50. Hudak PL, Cole DC, Haines AT. Understanding prognosis to improve rehabilitation: the example of lateral elbow pain. *Arch Phys Med Rehabil*. 1996;77:586-593. [http://dx.doi.org/10.1016/S0003-9993\(96\)90300-7](http://dx.doi.org/10.1016/S0003-9993(96)90300-7)
51. Huisstede BM, Miedema HS, Verhagen AP, Koes BW, Verhaar JA. Multidisciplinary consensus on the terminology and classification of complaints of the arm, neck and/or shoulder. *Occup Environ Med*. 2007;64:313-319. <http://dx.doi.org/10.1136/oem.2005.023861>
52. Jonsson P, Alfredson H, Sunding K, Fahlström M, Cook J. New regimen for eccentric calf-muscle training in patients with chronic insertional Achilles tendinopathy: results of a pilot study. *Br J Sports Med*. 2008;42:746-749. <http://dx.doi.org/10.1136/bjism.2007.039545>
53. Jull G, Sterling M, Kenardy J, Beller E. Does the presence of sensory hypersensitivity influence outcomes of physical rehabilitation for chronic whiplash? - A preliminary RCT. *Pain*. 2007;129:28-34. <http://dx.doi.org/10.1016/j.pain.2006.09.030>
54. Kalainov DM, Cohen MS. Posterolateral rotatory instability of the elbow in association with lateral epicondylitis. A report of three cases. *J Bone Joint Surg Am*. 2005;87:1120-1125. <http://dx.doi.org/10.2106/00004630.2005.02293>
55. Karkhanis S, Frost A, Maffulli N. Operative management of tennis elbow: a quantitative review. *Br Med Bull*. 2008;88:171-188. <http://dx.doi.org/10.1093/bmb/ldn036>
56. Keefe DT, Lintner DM. Nerve injuries in the throwing elbow. *Clin Sports Med*. 2004;23:723-742. <http://dx.doi.org/10.1016/j.csm.2004.04.012>
57. Khan KM, Forster BB, Robinson J, et al. Are ultrasound and magnetic resonance imaging of value in assessment of Achilles tendon disorders? A two year prospective study. *Br J Sports Med*. 2003;37:149-153. <http://dx.doi.org/10.1136/bjism.37.2.149>
58. Kochar M, Dogra A. Effectiveness of a specific physiotherapy regimen on patients with tennis elbow: clinical study. *Physiotherapy*. 2002;88:333-341. [http://dx.doi.org/10.1016/S0031-9406\(05\)60746-8](http://dx.doi.org/10.1016/S0031-9406(05)60746-8)
59. Konin GP, Nazarian LN, Walz DM. US of the elbow: indications, technique, normal anatomy,

and pathologic conditions. *Radiographics*. 2013;33:E125-E147. <http://dx.doi.org/10.1148/rg.334125059>

60. Kotnis NA, Chiavaras MM, Harish S. Lateral epicondylitis and beyond: imaging of lateral elbow pain with clinical-radiologic correlation. *Skeletal Radiol*. 2012;41:369-386. <http://dx.doi.org/10.1007/s00256-011-1343-8>
61. Kraushaar BS, Nirschl RP. Tendinosis of the elbow (tennis elbow). Clinical features and findings of histological, immunohistochemical, and electron microscopy studies. *J Bone Joint Surg Am*. 1999;81:259-278.
62. Krogh TP, Fredberg U, Stengaard-Pedersen K, Christensen R, Jensen P, Ellingsen T. Treatment of lateral epicondylitis with platelet-rich plasma, glucocorticoid, or saline: a randomized, double-blind, placebo-controlled trial. *Am J Sports Med*. 2013;41:625-635. <http://dx.doi.org/10.1177/0363546512472975>
63. Kurppa K, Viikari-Juntura E, Kuosma E, Huuskonen M, Kivi P. Incidence of tenosynovitis or peritendinitis and epicondylitis in a meat-processing factory. *Scand J Work Environ Health*. 1991;17:32-37. <http://dx.doi.org/10.5271/sjweh.1737>
64. Labelle H, Guibert R, Joncas J, Newman N, Fallaha M, Rivard CH. Lack of scientific evidence for the treatment of lateral epicondylitis of the elbow. An attempted meta-analysis. *J Bone Joint Surg Br*. 1992;74:646-651.
65. Lee DO, Gong HS, Kim JH, Rhee SH, Lee YH, Baek GH. The relationship between positive or negative phrasing and patients' coping with lateral epicondylitis. *J Shoulder Elbow Surg*. 2014;23:567-572. <http://dx.doi.org/10.1016/j.jse.2014.01.020>
66. Lim EC. Pain free grip strength test. *J Physiother*. 2013;59:59. [http://dx.doi.org/10.1016/S1836-9553\(13\)70152-8](http://dx.doi.org/10.1016/S1836-9553(13)70152-8)
67. Lim EC, Sterling M, Pedler A, Coombes BK, Vicenzino B. Evidence of spinal cord hyperexcitability as measured with nociceptive flexion reflex (NFR) threshold in chronic lateral epicondylalgia with or without a positive neurodynamic test. *J Pain*. 2012;13:676-684. <http://dx.doi.org/10.1016/j.jpain.2012.04.005>
68. Martinez-Silvestrini JA, Newcomer KL, Gay RE, Schaefer MP, Kortebein P, Arendt KW. Chronic lateral epicondylitis: comparative effectiveness of a home exercise program including stretching alone versus stretching supplemented with eccentric or concentric strengthening. *J Hand Ther*. 2005;18:411-419, quiz 420. <http://dx.doi.org/10.1197/j.jht.2005.07.007>
69. Maxwell S, Sterling M. An investigation of the use of a numeric pain rating scale with ice application to the neck to determine cold hyperalgesia. *Man Ther*. 2013;18:172-174. <http://dx.doi.org/10.1016/j.math.2012.07.004>
70. Milz S, Tischer T, Buettner A, et al. Molecular composition and pathology of entheses on the medial and lateral epicondyles of the humerus: a structural basis for epicondylitis. *Ann Rheum Dis*. 2004;63:1015-1021. <http://dx.doi.org/10.1136/ard.2003.016378>

[org/10.1136/ard.2003.016378](http://dx.doi.org/10.1136/ard.2003.016378)

71. Newcomer KL, Martinez-Silvestrini JA, Schaefer MP, Gay RE, Arendt KW. Sensitivity of the Patient-rated Forearm Evaluation Questionnaire in lateral epicondylitis. *J Hand Ther*. 2005;18:400-406. <http://dx.doi.org/10.1197/j.jht.2005.07.001>
72. Nijs J, Kosek E, Van Oosterwijck J, Meeus M. Dysfunctional endogenous analgesia during exercise in patients with chronic pain: to exercise or not to exercise? *Pain Physician*. 2012;15:ES205-ES213.
73. Nijs J, Van Houdenhove B. From acute musculoskeletal pain to chronic widespread pain and fibromyalgia: application of pain neurophysiology in manual therapy practice. *Man Ther*. 2009;14:3-12. <http://dx.doi.org/10.1016/j.math.2008.03.001>
74. Nijs J, Van Houdenhove B, Oostendorp RA. Recognition of central sensitization in patients with musculoskeletal pain: application of pain neurophysiology in manual therapy practice. *Man Ther*. 2010;15:135-141. <http://dx.doi.org/10.1016/j.math.2009.12.001>
75. O'Driscoll SW. Classification and evaluation of recurrent instability of the elbow. *Clin Orthop Relat Res*. 2000:34-43.
76. Paoloni JA, Appleyard RC, Nelson J, Murrell GA. Topical nitric oxide application in the treatment of chronic extensor tendinosis at the elbow: a randomized, double-blinded, placebo-controlled clinical trial. *Am J Sports Med*. 2003;31:915-920.
77. Paoloni JA, Murrell GA, Burch RM, Ang RY. Randomised, double-blind, placebo-controlled clinical trial of a new topical glyceryl trinitrate patch for chronic lateral epicondylitis. *Br J Sports Med*. 2009;43:299-302. <http://dx.doi.org/10.1136/bjism.2008.053108>
78. Papatheodorou LK, Baratz ME, Sotereanos DG. Elbow arthritis: current concepts. *J Hand Surg Am*. 2013;38:605-613. <http://dx.doi.org/10.1016/j.jhssa.2012.12.037>
79. Pasternack I, Tuovinen EM, Lohman M, Vehmas T, Malmivaara A. MR findings in humeral epicondylitis. A systematic review. *Acta Radiol*. 2001;42:434-440. <http://dx.doi.org/10.1080/028418501127347142>
80. Pattanittum P, Turner T, Green S, Buchbinder R. Non-steroidal anti-inflammatory drugs (NSAIDs) for treating lateral elbow pain in adults. *Cochrane Database Syst Rev*. 2013;5:CD003686. <http://dx.doi.org/10.1002/14651858.CD003686.pub2>
81. Paungmalai A, O'Leary S, Souvlis T, Vicenzino B. Hypoalgesic and sympathoexcitatory effects of mobilization with movement for lateral epicondylalgia. *Phys Ther*. 2003;83:374-383.
82. Peterson M, Butler S, Eriksson M, Svärdsudd K. A randomized controlled trial of eccentric vs. concentric graded exercise in chronic tennis elbow (lateral elbow tendinopathy). *Clin Rehabil*. 2014;28:862-872. <http://dx.doi.org/10.1177/0269215514527595>
83. Peterson M, Butler S, Eriksson M, Svärdsudd K. A randomized controlled trial of exercise versus

- wait-list in chronic tennis elbow (lateral epicondylitis). *Ups J Med Sci*. 2011;116:269-279. <http://dx.doi.org/10.3109/03009734.2011.600476>
84. Pienimäki T, Karinen P, Kemilä T, Koivukangas P, Vanharanta H. Long-term follow-up of conservatively treated chronic tennis elbow patients. A prospective and retrospective analysis. *Scand J Rehabil Med*. 1998;30:159-166.
 85. Pienimäki TT, Tarvainen TK, Siira PT, Vanharanta H. Progressive strengthening and stretching exercises and ultrasound for chronic lateral epicondylitis. *Physiotherapy*. 1996;82:522-530. [http://dx.doi.org/10.1016/S0031-9406\(05\)66275-X](http://dx.doi.org/10.1016/S0031-9406(05)66275-X)
 86. Poltawski L, Watson T. Measuring clinically important change with the Patient-rated Tennis Elbow Evaluation. *Hand Ther*. 2011;16:52-57. <http://dx.doi.org/10.1258/ht.2011.011013>
 87. Qi L, Zhu ZF, Li F, Wang RF. MR imaging of patients with lateral epicondylitis of the elbow: is the common extensor tendon an isolated lesion? *PLoS One*. 2013;8:e79498. <http://dx.doi.org/10.1371/journal.pone.0079498>
 88. Rabago D, Lee KS, Ryan M, et al. Hypertonic dextrose and morphuete sodium injections (prolotherapy) for lateral epicondylitis (tennis elbow): results of a single-blind, pilot-level, randomized controlled trial. *Am J Phys Med Rehabil*. 2013;92:587-596. <http://dx.doi.org/10.1097/PHM.0b013e31827d695f>
 89. Raman J, MacDermid JC, Grewal R. Effectiveness of different methods of resistance exercises in lateral epicondylitis—a systematic review. *J Hand Ther*. 2012;25:5-25, quiz 26. <http://dx.doi.org/10.1016/j.jht.2011.09.001>
 90. Ranger TA, Braybon WM, Purdam CR, Cook JL. Forearm position's alteration of radial-head impingement on wrist-extensor tendons. *J Sport Rehabil*. 2015;24:1-5. <http://dx.doi.org/10.1123/JSR.2013-0073>
 91. Rebbeck T, Moloney N, Azoory R, et al. Clinical ratings of pain sensitivity correlate with quantitative measures in people with chronic neck pain and healthy controls: cross-sectional study. *Phys Ther*. In press. <http://dx.doi.org/10.2522/ptj.20140352>
 92. Reichel LM, Milam GS, Sitton SE, Curry MC, Mehlhoff TL. Elbow lateral collateral ligament injuries. *J Hand Surg Am*. 2013;38:184-201, quiz 201. <http://dx.doi.org/10.1016/j.jhsa.2012.10.030>
 93. Rio E, Kidgell D, Cook J. Exercise reduces pain immediately and affects cortical inhibition in patellar tendinopathy [abstract]. *Br J Sports Med*. 2014;48:A57-A58. <http://dx.doi.org/10.1136/bjsports-2014-094114.87>
 94. Rompe JD, Overend TJ, MacDermid JC. Validation of the Patient-rated Tennis Elbow Evaluation Questionnaire. *J Hand Ther*. 2007;20:3-10, quiz 11. <http://dx.doi.org/10.1197/j.jht.2006.10.003>
 95. Rosenbaum R. Disputed radial tunnel syndrome. *Muscle Nerve*. 1999;22:960-967. [http://dx.doi.org/10.1002/\(SICI\)1097-4598\(199907\)22:7<960::AID-MUS26>3.0.CO;2-C](http://dx.doi.org/10.1002/(SICI)1097-4598(199907)22:7<960::AID-MUS26>3.0.CO;2-C)
 96. Ruch DS, Papadonikolakis A, Campolattaro RM. The posterolateral plica: a cause of refractory lateral elbow pain. *J Shoulder Elbow Surg*. 2006;15:367-370. <http://dx.doi.org/10.1016/j.jse.2005.08.013>
 97. Schabrun SM, Hodges PW, Vicenzino B, Jones E, Chipchase LS. Novel adaptations in motor cortical maps: the relation to persistent elbow pain. *Med Sci Sports Exerc*. 2015;47:681-690. <http://dx.doi.org/10.1249/MSS.0000000000000469>
 98. Schmid AB, Brunner F, Luomajoki H, et al. Reliability of clinical tests to evaluate nerve function and mechanosensitivity of the upper limb peripheral nervous system. *BMC Musculoskelet Disord*. 2009;10:11. <http://dx.doi.org/10.1186/1471-2474-10-11>
 99. Shiri R, Viikari-Juntura E, Varonen H, Heliövaara M. Prevalence and determinants of lateral and medial epicondylitis: a population study. *Am J Epidemiol*. 2006;164:1065-1074. <http://dx.doi.org/10.1093/aje/kwj325>
 100. Silbernagel KG, Thomeé R, Eriksson BI, Karlsson J. Continued sports activity, using a pain-monitoring model, during rehabilitation in patients with Achilles tendinopathy: a randomized controlled study. *Am J Sports Med*. 2007;35:897-906. <http://dx.doi.org/10.1177/0363546506298279>
 101. Smidt N, Assendelft WJ, Arola H, et al. Effectiveness of physiotherapy for lateral epicondylitis: a systematic review. *Ann Med*. 2003;35:51-62.
 102. Smidt N, Lewis M, van der Windt DA, Hay EM, Bouter LM, Croft P. Lateral epicondylitis in general practice: course and prognostic indicators of outcome. *J Rheumatol*. 2006;33:2053-2059.
 103. Sniijders CJ, Volkers AC, Mechelse K, Vleeming A. Provocation of epicondylalgia lateralis (tennis elbow) by power grip or pinching. *Med Sci Sports Exerc*. 1987;19:518-523.
 104. Stasinopoulos D, Stasinopoulou K, Johnson MI. An exercise programme for the management of lateral elbow tendinopathy. *Br J Sports Med*. 2005;39:944-947. <http://dx.doi.org/10.1136/bjism.2005.019836>
 105. Sterling M, Hendrikz J, Kenardy J. Similar factors predict disability and posttraumatic stress disorder trajectories after whiplash injury. *Pain*. 2011;152:1272-1278. <http://dx.doi.org/10.1016/j.pain.2011.01.056>
 106. Stratford PW, Levy DR. Assessing valid change over time in patients with lateral epicondylitis at the elbow. *Clin J Sport Med*. 1994;4:88-91.
 107. Svernlöv B, Adolfsson L. Non-operative treatment regime including eccentric training for lateral humeral epicondylalgia. *Scand J Med Sci Sports*. 2001;11:328-334.
 108. van Rijn RM, Huisstede BM, Koes BW, Burdorf A. Associations between work-related factors and specific disorders at the elbow: a systematic literature review. *Rheumatology (Oxford)*. 2009;48:528-536. <http://dx.doi.org/10.1093/rheumatology/kep013>
 109. Vicenzino B. Lateral epicondylalgia: a musculoskeletal physiotherapy perspective. *Man Ther*. 2003;8:66-79. [http://dx.doi.org/10.1016/S1356-689X\(02\)00157-1](http://dx.doi.org/10.1016/S1356-689X(02)00157-1)
 110. Vicenzino B, Brooksbank J, Minto J, Offord S, Paungmali A. Initial effects of elbow taping on pain-free grip strength and pressure pain threshold. *J Orthop Sports Phys Ther*. 2003;33:400-407. <http://dx.doi.org/10.2519/jospt.2003.33.7400>
 111. Vicenzino B, Paungmali A, Buratowski S, Wright A. Specific manipulative therapy treatment for chronic lateral epicondylalgia produces uniquely characteristic hypoalgesia. *Man Ther*. 2001;6:205-212. <http://dx.doi.org/10.1054/math.2001.0411>
 112. Vicenzino B, Paungmali A, Teys P, Mulligan's mobilization-with-movement, positional faults and pain relief: current concepts from a critical review of literature. *Man Ther*. 2007;12:98-108. <http://dx.doi.org/10.1016/j.math.2006.07.012>
 113. Vicenzino B, Wright A. Lateral epicondylalgia I: epidemiology, pathophysiology, aetiology and natural history. *Phys Ther Rev*. 1996;1:23-34. <http://dx.doi.org/10.1179/ptr.1996.1.1.23>
 114. Wainner RS, Fritz JM, Irrgang JJ, Boninger ML, Delitto A, Allison S. Reliability and diagnostic accuracy of the clinical examination and patient self-report measures for cervical radiculopathy. *Spine (Phila Pa 1976)*. 2003;28:52-62.
 115. Walker-Bone K, Palmer KT, Reading I, Coggon D, Cooper C. Occupation and epicondylitis: a population-based study. *Rheumatology (Oxford)*. 2012;51:305-310. <http://dx.doi.org/10.1093/rheumatology/ker228>
 116. Walker-Bone K, Palmer KT, Reading I, Coggon D, Cooper C. Prevalence and impact of musculoskeletal disorders of the upper limb in the general population. *Arthritis Rheum*. 2004;51:642-651. <http://dx.doi.org/10.1002/art.20535>
 117. Walton MJ, Mackie K, Fallon M, et al. The reliability and validity of magnetic resonance imaging in the assessment of chronic lateral epicondylitis. *J Hand Surg Am*. 2011;36:475-479. <http://dx.doi.org/10.1016/j.jhsa.2010.11.040>
 118. Whitehurst DG, Bryan S, Lewis M, Hill J, Hay EM. Exploring the cost-utility of stratified primary care management for low back pain compared with current best practice within risk-defined subgroups. *Ann Rheum Dis*. 2012;71:1796-1802. <http://dx.doi.org/10.1136/annrheumdis-2011-200731>
 119. Wilk KE, Voight ML, Keirns MA, Gambetta V, Andrews JR, Dillman CJ. Stretch-shortening drills for the upper extremities: theory and clinical application. *J Orthop Sports Phys Ther*. 1993;17:225-239. <http://dx.doi.org/10.2519/jospt.1993.17.5.225>
 120. Wixom SM, LaStayo P. A potential classification model for individuals with tennis elbow. *J Hand Ther*. 2012;25:418-420, quiz 421. <http://dx.doi.org/10.1016/j.jht.2012.06.007>

